

Radiological identification of an ibis mummy

F. J. Tomás Gimeno

Tomás Gimeno, F. J., 1997. Radiological identification of an ibis mummy. *Misc. Zool.*, 20.2: 133-138.

Radiological identification of an ibis mummy.—X-rays of the mummy were taken and compared with those of the craniums of three species of the Threskiornithidae family (*Threskiornis aethiopicus*, *Plegadis falcinellus* and *Geronticus eremita*). It was concluded that the mummy was of a *Threskiornis aethiopicus* (Sacred ibis). Radiology is a useful tool in the identification and study of mummified animals, especially of species which are genetically and morphologically close. It is a non-invasive technique that does not imply alteration or destruction of the archaeological piece studied.

Key words: Ibis, *Threskiornis aethiopicus*, Mummy, Radiology, Identification, Paleozoology.

(Rebut: 4 III 97; Acceptació condicional: 3 VI 97; Acc. definitiva: 9 IX 97)

F. Javier Tomás, c/ Lluís Sagnier 13, 1^{er} 1^a, 08041 Barcelona, Espanya (Spain).

Introduction

Mummification was a very widespread practice in certain ancient cultures, and was conceived as a means of preparing the dead for life after death. The Egyptians were very prolific and skilled in this practice reaching great levels of sophistication and technique.

The study of these mummies is of great historic and scientific interest, although it resulted in necropsies and partial or total destruction of many mummies. With the discovery of X-ray in 1895, a non-invasive means of research was found whose characteristics suggested interesting future applications. Three years later, in 1898, X-rays were used for the first time on human mummies by Petrie (GRAY, 1973; MARX & D' AURIA, 1986; BRAUENSTEIN et al., 1988).

Archaeologists and palaeontologists have since used X-rays frequently in the study of human mummies (GRAY, 1973; FODOR et al., 1983; BRAUENSTEIN et al., 1988). The technique has provided a great amount of valuable information about the life (food, longevity, illnesses, degenerative processes, treatment of diseases and injuries and so on), the death and its causes, and also about the post-mortems carried out on man in antiquity (GRAY, 1973; FODOR et al., 1983). Archaeologists are able to date the mummy from the study of the embalming technique used (VAHEY & BROWN, 1984).

X-rays have made it possible to detect jewels, charms, metallic objects and other material whose composition and density are sufficient to attenuate the passing of radiation (FODOR et al., 1983).

Such research was first carried out using conventional radiography, but the technical advances and new discoveries in the field of imaging diagnosis have led to more sophisticated techniques which are progressively being applied. Human mummies have now been examined by conventional computerized scanning equipment (HARWOOD-NASH, 1979; VAHEY & BROWN, 1984; MARX & D' AURIA, 1986), analysed by means of three dimensional reconstructions (MARX & D' AURIA, 1988) and even subjected to nuclear magnetic resonance following hydration of the remains (PIEPENBRINK et al., 1986).

However, the Egyptians did not only embalm humans, but also a large variety of

animal species, ranging from fish and birds to crocodiles, cats, monkeys and even bulls (KLEISS, 1987).

The study of these animal mummies not only reveals the content and techniques of the embalment, but also provides valuable data for palaeozoological studies. Nonetheless, little research using X-rays has been done other than to illustrate and complement more general studies.

Identification by means of radiology of animal mummies has been dealt with in two previous publications. The first was the identification of a small mummy found in the grave of the queen Makare, erroneously thought to be her daughter. Radiological study revealed that the remains were in fact of a small *Papio hamadryas* (Baboon) (KLEISS, 1987). The other work concerns the identification of a bird mummy owned by the Musée Zoologique de l'Université Louis Pasteur of Strasbourg, and catalogued as the "mummy of a parrot". Faced with the justifiable doubt over the identity of these remains, they were duly X-rayed. The analysis of the radiographs taken by experts from the museum led to the conclusion that the remains were of a *Accipiter nisus* (Sparrow hawk) (ABGRALL, 1988).

This paper presents a study of the identification of a mummy by means of radiography and its subsequent comparison with X-ray photographs of similar species belonging to the same zoological family.

Material and methods

The subject analysed comes from the Upper Nile and dates from the Late Period (715-332 B.C.). It belongs to the Museu Egipci of Barcelona (catalogue number E-328), part of the Fundació Arqueològica Clos.

Conventional medical radiological equipment was used, consisting of an X-ray tube with a Heliophos 604 generator (Siemens), radiographic film sensitive to blue and a Novodur cassette (Agfa) with a calcic tungsten double intensifying screen of standard type. The exposure to the X-rays was direct, without an anti-diffusion grid, and at a focal film distance of 150 cm to minimise the magnification on the resulting image. The shot was taken with a thin focus with a

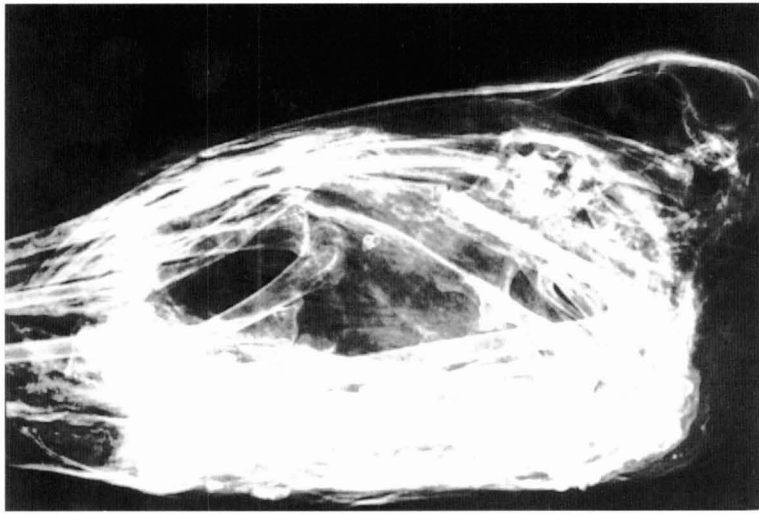


Fig. 1. Lateral radiography of the ibis mummy. The head is turned and resting on the animal's back.

Radiografía lateral de la momia de ibis. La cabeza está girada y apoyada sobre el dorso del animal.

voltage of 44-52 kV, a strength of 50 mA and an exposure time of 0.12-0.20 sec. An Agfa developer and fixer was used to process the films.

One radiograph was taken laterally and one frontally (superoinferior), thereby checking the content, position and general condition of the mummy. For the study only the lateral projection (fig. 1) was used: the frontal shot was rejected due to the fact that the superposition of the cranium with the other bones of the body (spinal column, ribs, extremities and so on) gave a confusing, unclear image.

For the control study, the three species of the Threskiornithidae family, known in Ancient Egypt (HOULIHAN, 1988), were chosen:

- *Threskiornis aethiopicus* (Sacred ibis), one of the most frequently mummified birds with up to 1.5 million specimens exhumed from the catacombs of Saqqara (GOODMAN, 1989).
- *Plegadis falcinellus* (Glossy ibis), also found in mummified form (GOODMAN, 1989).
- *Geronticus eremita* (Hermit ibis), which despite not having been found as a mummy, is

widely represented in ancient Egyptian art and iconography (HOULIHAN, 1988).

The above specimens belong to the collection of the Museu de Zoologia of Barcelona.

The craniums of these species were X-rayed in the lateral position, using the same equipment and technical parameters as those used for the embalmed specimen.

Results

All radiographs were studied individually and analysed. A comparative study was undertaken of the radiographic images of each on the museum specimens with the corresponding image of the mummy.

From the outset the detailed observation of the bone structure ruled out the possibility of the cranium corresponding to a *Plegadis falcinellus* due to a marked difference with regard to the mummy.

Two characteristics were definitive in the identification of the cranium. The first was

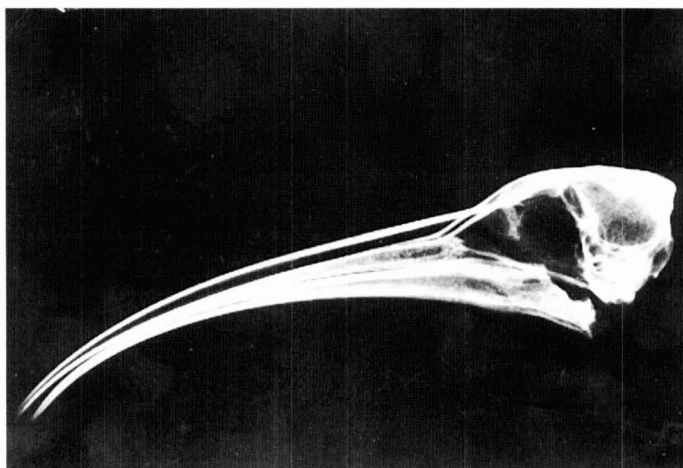


Fig. 2. Lateral radiography of a dry cranium of the *Geronticus eremita*.
Radiografía lateral de un cráneo seco de Geronticus eremita.

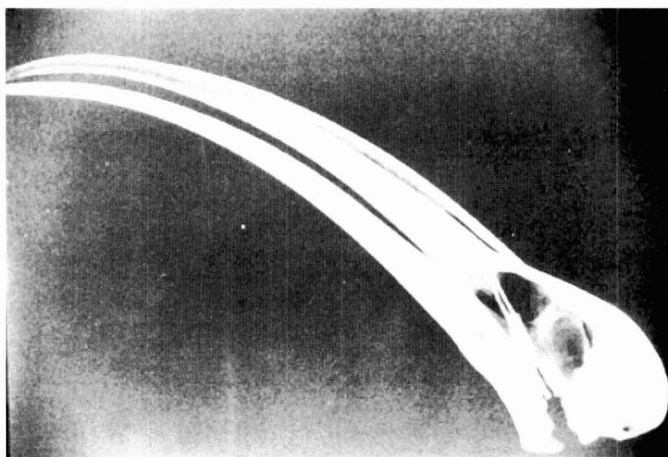


Fig. 3. Lateral radiography of a dry cranium of the *Threskiornis aethiopicus*.
Radiografía lateral de un cráneo seco de Threskiornis aethiopicus.

the presence of the external occipital protuberance in the upper and near areas of the parietal bones, in the joint with the occipital bone in the cranium of the *Geronticus*

eremita (fig. 2) which was absent in the *Threskiornis aethiopicus* (fig. 3) as well as in the mummified specimen.

The other characteristic corresponded to

the form and size of the eye socket (orbit). To appraise this, the quotient was obtained between the length of the zygomatic bone at the base of the socket and its maximum height. The latter was measured from the zygomatic bone to the highest point of the socket. The quotient was 1.86 for the *Geronticus eremita* and 2.07 for both the *Threskiornis aethiopicus* and the mummy.

The characteristics were considered sufficient to identify the mummified bird as belonging to the *Threskiornis aethiopicus* species.

The possibility of it belonging to another species of the same *Threskiornis* genus was rejected as its areas of distribution are very far from the African continent (DEL HOYO et al., 1992).

Discussion

Since its beginnings, radiology has proved a useful non-invasive way of discovering the contents of mummies, especially human ones (GRAY, 1973; FODOR et al., 1983; VAHEY & BROWN, 1984; MARX & D'AURIA, 1986; BRAUENSTEIN et al., 1988).

It allows study of the symptoms of disease in human corpses and embalming techniques, as well as revealing jewels or other objects that may be inside.

In animal mummies radiology can be used to verify whether the contents correspond to one or more animals, if they are fragments which are difficult to identify, or if they are filled with mud or other materials (KLEISS, 1987).

Here has been shown the use of radiology as a method of specific identification of animal mummies, particularly important in species which are morphologically similar or genetically close, by means of a comparative study with X-rays of specimens from a museum collection. This can be useful in the case of bird of prey. In excavations carried out in Egypt, the remains of 30 different species have been identified, eight of which were hawks (genus *Falco*) (GOODMAN, 1989). Although different in size, externally were similar and only direct views of the interior were able to identify the bird.

Some species belonging to the fauna of the region have not been found embalmed,

as in the case of the *Geronticus eremita*. They may in fact have passed unnoticed or have been confused with other more common species. By means of this comparative study, radiology would also facilitate the analysis of a large quantity of remains in museums which are supposedly classified correctly, without damaging them. Moreover, this technique makes it possible to study a large number of specimens in little time.

Furthermore, the application of X-rays is not limited to man-made mummies. They can be extended to those natural mummies whose external appearance does not allow recognition of the animal and which, for scientific or documental interest, are best kept as they were found.

Radiology is a simple technique which provides almost immediate results at low cost. Any conventional medical or veterinary radiological equipment can be used, requiring minimum handling and without the need to interfere with the archaeological specimen.

Acknowledgements

I would like to express my gratitude to Jordi Clos who kindly allowed access to the mummy for examination, and supplied all the necessary documentation. I would also like to thank Francesc Uribe for allowing access to the museum's materials and for his advice and comments on the study, and finally my thanks to Gloria Masó, who selected the pieces for study and took part in taking the radiographs and the subsequent identification of the ibis mummy.

Resumen

Identificación radiológica de una momia de ibis

La momificación era una práctica muy extendida en algunas culturas antiguas, especialmente en la egipcia. De su estudio se puede obtener información muy valiosa para arqueólogos y paleopatólogos, y en el caso de las momias de animales, para los paleozoólogos.

Hasta el descubrimiento de los rayos-X,

en 1895, el estudio de dichas momias comportaba su destrucción parcial o total, pero la aplicación de las propiedades de esta nueva radiación permitió comprobar su contenido sin alterar la pieza arqueológica. Se han practicado múltiples estudios y se han hecho importantes descubrimientos en los restos embalsamados de seres humanos, aplicando las nuevas tecnologías en el diagnóstico por la imagen pero muy poco se ha investigado en las momias de animales. Se presenta un método sencillo por el que, gracias a la aplicación de los rayos-X, podemos identificar la especie a la que pertenece el ejemplar momificado, respetando su integridad. Éste consiste en el estudio comparativo del cráneo del animal embalsamado una vez radiografiado, con el de las radiografías de especies afines.

Para el estudio se dispuso de una momia de ibis, procedente del alto Nilo y datado en la Baja Época (715-332 a.C.), propiedad del Museu Egipci de Barcelona (número de catálogo E-328), de la Fundació Arqueològica Clos.

En la ejecución de las radiografías se utilizó un equipo de radiología médica convencional. Se realizaron dos proyecciones, una lateral (fig. 1) y otra posteroanterior, siendo descartada esta última por presentar múltiples superposiciones que dificultaban la identificación de las diferentes estructuras craneales.

Para el estudio comparativo se escogieron las tres especies de la familia Threskiornidae, conocidas en el Antiguo Egipto: *Threskiornis aethiopicus* (ibis sagrado), una de las aves momificada en mayor número (hasta 1,5 millones de ejemplares exhumados en las catacumbas de Saqqara); *Plegadis falcinellus* (morito), también hallada en forma de momia; *Geronticus eremita* (ibis eremita), que pese a no haberse encontrado momificada, está ampliamente representada en el arte y la iconografía del antiguo Egipto. Estos ejemplares pertenecían a la colección del Museu de Zoologia de Barcelona. Se radiografiaron los cráneos de estas especies en posición lateral, usándose el mismo equipo y parámetros técnicos que los empleados en el ejemplar embalsamado (figs. 2, 3). Tras un examen minucioso y comparando las radiografías de estos ejemplares con la de la mo-

mia, se identificó ésta como perteneciente a la especie *Threskiornis aethiopicus*.

Es ésta una técnica simple y de fácil ejecución, con un bajo coste y que puede permitir la identificación de un gran número de momias animales en poco tiempo, mediante la utilización de equipos convencionales de radiología médica o veterinaria.

References

- ABGRALL, R., 1988. La nature vue aux rayons X. *Le Manipulateur*, 91: 19-20.
- BRAUENSTEIN, E. M., WHITE, S. J., RUSSELL, W. & HARRIS, J. E., 1988. Paleoradiologic evaluation of the Egyptian royal mummies. *Skeletal Radiol.*, 17: 348-352.
- DEL HOYO, L., ELLIOTT, A. & SARGATAL, J. (Eds.), 1992. *Handbook of the Birds of the World. Vol. 1.* Lynx edicions, Barcelona.
- FODOR III, J., MALOTT, J. C. & KING, A. Y., 1983. The radiographic investigation of two Egyptian mummies. *Radiol. Technol.*, 54 (6): 443-448.
- GOODMAN, S. M., 1989. *The birds of Egypt.* Oxford University Press, Oxford.
- GRAY, P. H. K., 1973. The radiography of mummies of ancient Egyptians. *J. Human Evol.*, 2: 51-53.
- HARWOOD-NASH, D. C. F., 1979. Computed tomography of ancient Egyptian mummies. *J. Comput. Assist. Tomogr.*, 3 (6): 768-773.
- HOULIHAN, P. F., 1988. *The birds of ancient Egypt.* The American University in Cairo Press, Cairo.
- KLEISS, E., 1987. Tiermumien im Alten Agypten. *Anat. Histol. Embryol.*, 16: 198-205.
- MARX, M. & D' AURIA, S. H., 1986. CT examination of eleven Egyptian mummies. *RadioGraphics*, 6: 321-330.
- 1988. Three-dimensional CT reconstructions of an ancient human Egyptian mummy. *AJR*, 150: 147-149.
- PIEPENBRINK, H., FRAHM, J., HAASE, A. & MAITHAEI, D., 1986. Nuclear magnetic resonance imaging of mummified corpses. *Am. J. Phys. Anthropol.*, 70: 27-28.
- VAHEY, T. & BROWN, D., 1984. Comely Wenuhotep: Computed tomography of an Egyptian mummy. *J. Comput. Assist. Tomogr.*, 8 (5): 992-997.